

# Yellow Nail Syndrome and Adnexal Tumour: Causal or Casual Association?

Vitorino Modesto dos Santos<sup>1,2</sup>, Herberth Vera Cruz Furtado Marques Jr<sup>2</sup>, Camila do Carmo Lima<sup>2</sup>, Thiago Zavascki Turra<sup>2</sup>, Pedro Robério de Melo Nogueira Jr<sup>2</sup> and Lia Nogueira Lima<sup>2</sup>

Catholic University Medical Course<sup>1</sup> and Department of Internal Medicine from Armed Forces Hospital<sup>2</sup>, Brasilia – DF, Brazil

---

## ABSTRACT

---

The yellow nail syndrome is an uncommon condition characterised by dystrophic nails, pulmonary disturbances and lymph oedema. In Brazil as well as in India, this syndrome has been scarcely described, at least in part due to diagnosis pitfalls related with darker skin pigmentation. A case of adnexal malignancy developing several decades after initial signs of yellow nail syndrome is reported in a 61-year-old Brazilian female admitted for evaluation of peripheral oedema. She reported recurrent sinusitis and bronchitis, and three antecedent pneumonias. Physical examination showed yellow thickened nails and lower limb oedema, and a painless huge adnexal mass. Diverse tumours have been described associated with yellow nail syndrome; however, associations can also occur by chance. The present report attempts to raise the awareness about casual co-existence of malignancy and the syndrome. [Indian J Chest Dis Allied Sci 2010;52:51-53]

**Key words:** Yellow nail syndrome, Oedema, Respiratory infection, Adnexal tumour, Association.

---

## INTRODUCTION

---

The yellow nail syndrome is an uncommon condition of unclear aetiology, for the first time reported in 1964.<sup>1</sup> About a hundred cases described, which are characterised by the progressive association of nail changes, recurrent respiratory disturbances and lymph oedema. Notwithstanding, only two of these manifestations are enough to establish the diagnosis.<sup>2,3</sup> Among South American as well as Indian people, this syndrome has been scarcely described,<sup>2,4</sup> at least in part because of under-diagnosis or under-reporting. Furthermore, dermatological diagnostic clues may be not easily appreciable in those patients with darker skin pigmentation.<sup>2,4</sup> The respiratory disturbances include asthma, bronchitis, sinusitis, bronchiectasis, and recurrent pneumonitis and pleural effusions.<sup>1,5</sup> Nail changes may occur in some or all digits, and thickening, hardening, excessive convexity, transversal ridging, onycholysis, onychorrexia, paronychia, deficient cuticles, absence of lunules, and slow growth have also been found.<sup>1-3</sup> Morphologic and functional changes of the lymph vessels play a role, as well as diverse other factors, including autoimmune diseases, hypoalbuminemia, drug effects and malignancies.<sup>1-3,6,7</sup> Vast majority of cases are idiopathic, but familiar and acquired cases have been also described.<sup>5-7</sup> The purpose is to report a typical

case of yellow nail syndrome casually co-existent with adnexal tumour, emphasising that dermatological features can raise the suspicion about this condition.

---

## CASE REPORT

---

A 61-year-old Brazilian female was admitted because of recent oedema. She was known to have hypertension and diabetes mellitus, and had been hospitalised several times because of recurrent respiratory infections. She was being treated with enalapril, hydrochlorothiazide, aspirin, metformin and cilostazol. She complained of appetite loss, aesthenia, breath discomfort and oedema. On physical examination she was apathetic, with Hippocratic facies, pale mucosa and oedema. The lungs were normal, while an abdominal mass extending from the pelvis to the left flank was palpated. All the finger nails were yellow coloured with indistinct lunules, and the toe nails were also dystrophic (Figure 1). She did not remember exactly when the yellow nail discolouration first appeared, but this change was observed several decades ago. Peripheral cyanosis and bilateral oedema were seen in the lower limbs (Figures 1c and 1d). Blood tests were unremarkable, except for very high CA-125 (411 U/mL), low serum albumin (2.6 mg/dL), and high urea (68 mg/dL). Tests for onychomycosis were negative. Computerised tomography revealed scattered

---

[Received: June 09, 2009; accepted after revision: August 12, 2009]

**Correspondence and reprint requests:** Vitorino Modesto dos Santos, SMPW Quadra 14 Conjunto 2 Lote 7 Casa A. 71.745-140, Brasília-DF, Brazil; Phone: 61-33802666; Fax: 61-32331599. E-mail: vitorinomodesto@gmail.com

nodules in the liver parenchyma (Figure 2). Pelvic ultrasound showed a mass (20.7 cm x 15.8 cm x 14.7 cm) with a solid and cystic complex internal structure (Figure 3). The lymphoscintigraphy disclosed inguinal and intrapelvic lymph stasis after 24 hours (Figure 4).

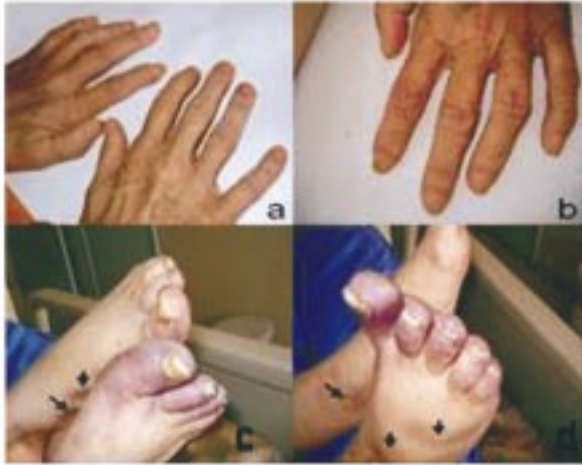

Figure 1. Yellow nail discoloration and absence of lunules in the hand fingers (a and b), in addition to dystrophic yellow nails and pitting oedema (arrows) in both lower limbs (c and d).

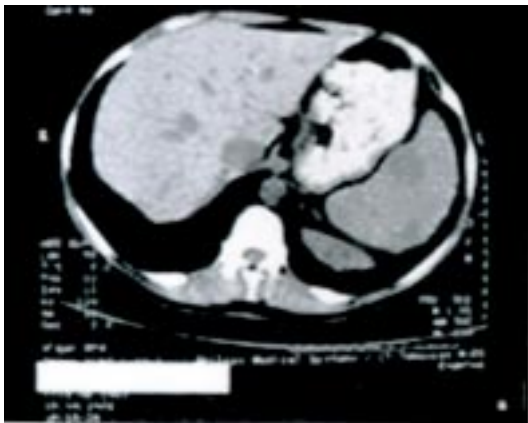

Figure 2. Computerised tomography of the scattered nodules in the liver parenchyma.

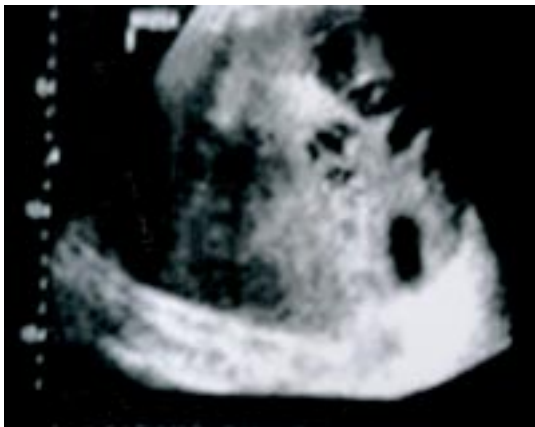

Figure 3. Ultrasound features of the large and complex left adnexal tumour.

Additionally, ultrasound study of the mass showed classic malignant features, images of metastases were found in the liver parenchyma, and CA-125 determination was very elevated. The tumour sample features disclosed primary undifferentiated ovarian cancer, while yellow nail syndrome could be characterised by clinical and imaging data. The patient did not show any improvement in spite of the clinical care and the nutritional support. She developed irreversible respiratory and renal failure and died 12 days after the admission.

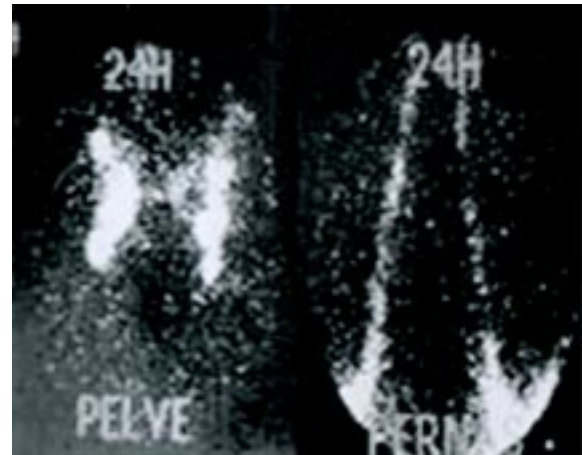


Figure 4. Lymphoscintigraphy showing pelvic (PELVE) and inguinal (PERNAS) stasis after 24 hours.

## DISCUSSION

Yellow nail syndrome occurs more frequently among females (male:female=1:1.6) and in middle-aged individuals; notwithstanding, cases have been described since the infancy until the eighth decade of life.<sup>5</sup> This patient presented with the complete triad of the syndrome, as seen in a third of the cases.<sup>6,8</sup> The time elapsed for the typical features to appear may be very long and they may appear in a variable order.<sup>4,6</sup> In the present case, accentuated pitting oedema was observed in both legs and feet, indicative of a mixed origin (lymphoedema and hypoalbuminemia), as has been described in some individuals. Entities as myxoedema, onychomycosis, lichen planus and traumatic pachyonychia were ruled out. Although the aetiology of the syndrome is more often obscure, diverse disorders have been described in the lymphatic drainage, which could explain inclusive some of the nail changes.<sup>6,8</sup> The lymphatic disturbances can be secondary and have a functional nature, because the reversibility observed in some un-treated patients did not support purely anatomic factors.<sup>5</sup> Yellow nail syndrome is considered to be an autosomal dominant condition with a variable expression, which is not confirmed in many of the cases.<sup>8,9</sup> A similar condition was not present among the relatives of this

patient. The syndrome may co-exist with malignancies like breast, larynx, lung, endometrium, and gall bladder carcinomas, in addition to lymphoma and metastatic sarcoma and melanoma.<sup>6</sup> Moreover, associations have been described with thyroid disease, hypogammaglobulinemia, nephrotic syndrome, protein-losing enteropathy, obstructive sleep apnoea, rheumatoid arthritis, ocular changes, xanthogranulomatous pyelonephritis, tuberculosis, and acquired immunodeficiency syndrome.<sup>1-3,6</sup> Furthermore, a possible paraneoplastic origin is considered in some cases, but the span of time between the onset of clinical features and the diagnosis of malignancy may be very long, and many times the clinical disturbances do not improve following the treatment of malignancy.<sup>6</sup> We report the case of a 61-year-old nulliparous patient with long-standing yellow nails and recurrent respiratory infections, who was admitted with an adnexal tumour and liver metastases. Adnexal metastases from breast or gastrointestinal cancers were ruled out by routine procedures. She showed oedema in the lower limbs and stasis in the pelvic and inguinal lymphatic drainage; although pleural effusion was not detected (Figure 5) this

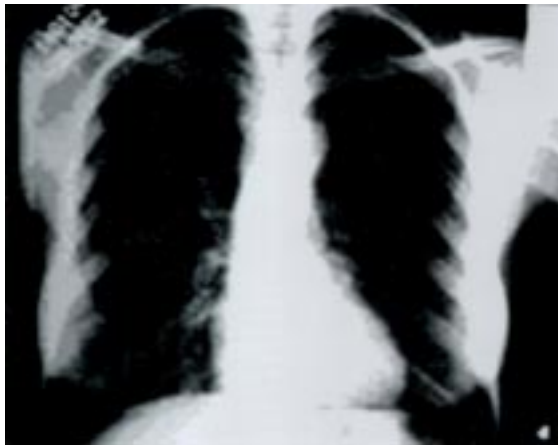


Figure 5. Chest radiograph (postero-anterior view) with no remarkable findings.

may be the last feature of the syndrome to appear.<sup>2-4,6</sup> As expected in a postmenopausal woman with undifferentiated tumour, CA-125 level was high;<sup>10</sup> as her cancer was diagnosed late in stage IV, she succumbed to her illness. Worthy of note, the nail changes appeared several decades before any evidence of malignancy. Therefore, the hypothesis of association without pathophysiological correlation, which occurred by chance between this adnexal malignancy and the yellow nail syndrome, seems strengthened.

---

## REFERENCES

---

1. Samman PD, White WF. The "yellow nail syndrome". *Br J Dermatol* 1964;76:153-7.
2. Dixit R. Yellow nail syndrome. *Lung India* 2007;24:66-8.
3. Mehta Y, Vasanth V, Balachandran C. Yellow nails following hemodialysis in chronic renal failure: is it yellow nail syndrome or a variant? *Dermatol Online J* 2008;14:20.
4. Nair VK, Sukumaran P. Yellow nail syndrome: a rarity in Indians? *Indian J Chest Dis Allied Sci* 1996;38:39-43.
5. Maldonado F, Tazelaar HD, Wang CW, Ryu JH. Yellow Nail Syndrome: analysis of 41 consecutive Patients. *Chest* 2008;134:375-81.
6. Iqbal M, Rossoff LJ, Marzouk KA, Steinberg HN. Yellow nail syndrome: resolution of yellow nails after successful treatment of breast cancer. *Chest* 2000;117:1516-8.
7. Nordkild P, Kromann-Andersen H, Struve-Christensen E. Yellow nail syndrome - the triad of yellow nails, lymphedema and pleural effusions: a review of the literature and a case report. *Acta Med Scand* 1986;219:221-7.
8. Wells GC. Yellow nail syndrome with familiar primary hypoplasia of lymphatics, manifest late in life. *Proc R Soc Med* 1966;59:447.
9. Hoque SR, Mansour S, Mortimer PS. Yellow nail syndrome: not a genetic disorder? Eleven new cases and a review of the literature. *Br J Dermatol* 2007;156:1230-4.
10. Van Calster B, Timmerman D, Bourne T, Testa AC, Van Holsbeke C, Domali E, et al. Discrimination between benign and malignant adnexal masses by specialist ultrasound examination versus serum CA-125. *J Natl Cancer Inst* 2007;99:1706-14.