

Case Report

An Unusual Case of Invasive *Aspergillus* Ulcerative Tracheobronchitis Without Involvement of Lung Parenchyma in a Post-Renal Transplant Patient

Sandeep S. Tilve¹, Arun B. Shah², Pralhad P. Prabhudesai¹ and Chandralekha Tampi³

Departments of Respiratory Medicine¹, Nephrology² and Pathology³, Lilavati Hospital, Mumbai, India

ABSTRACT

We present the case of a 54-year-old male, who presented with respiratory complaints four months after he underwent renal transplantation. Bronchoscopy showed ulcerated mucosa of the left main bronchus and computed tomography (CT) of the thorax showed foci of air within the bronchial wall. A biopsy from the lesion showed septate fungal hyphae, dichotomously branching at acute angles. A locally invasive *Aspergillus* ulcerative tracheobronchitis with no parenchymal involvement is an important cause of tracheobronchitis in post-renal transplant patients. An early diagnosis and institution of appropriate treatment can improve the outcome. A combination treatment of caspofungin and voriconazole can be considered if patient is not responding to voriconazole alone. [Indian J Chest Dis Allied Sci 2013;55:221-223]

Key words: Tracheobronchitis, Invasive aspergillosis, Post-renal transplant.

INTRODUCTION

Inhalation of air borne *Aspergillus* spores result in colonisation of respiratory mucosal surfaces. The progression from colonisation to tissue invasion depends on the person's immune status and local defence mechanisms. Different morphological forms¹ of the disease, namely, obstructive tracheobronchitis, pseudomembranous tracheobronchitis and ulcerative tracheobronchitis have been described in the literature. It is possible that all these forms represent progressive spectrum of the disease.

A locally invasive aspergillosis with ulcerative lesions with no parenchymal involvement is an important cause of tracheobronchitis in post-renal transplant patients. Evaluation with computed tomography (CT), bronchoscopy and histopathological examination of the biopsy specimen are often required to establish the diagnosis. A combination treatment of caspofungin and voriconazole can be considered if patient is not responding to voriconazole alone.

CASE REPORT

A 54-year-old male presented with persistent cough since more than two weeks, which was present throughout the day and used to increase on lying

down position. It was not associated with breathlessness, chest pain or haemoptysis. There was no fever. He had hypertension for which he was receiving treatment with losartan 50mg daily for the last five years. He also had diabetes mellitus for the preceding 20 years and was being treated with oral hypoglycaemic drugs. As he developed chronic kidney disease (CKD) due to diabetic nephropathy he had undergone renal transplantation four months before presentation with his spouse being the live donor. He was on immunosuppressant drugs tacrolimus 0.1mg/kg/day, mycophenolate 1g twice daily and prednisolone 1mg/kg/day since then.

On physical examination, he was afebrile. His heart rate was 84/min, respirations 18/min and blood pressure was 130/80. Pulse oximetry revealed an oxygen saturation of 99% on room air. On auscultation harsh breath sounds, rhonchi were evident all over the lung fields. Review of other systems did not show any abnormality. His laboratory findings included haemoglobin of 10.3 g/dL; total leukocyte count 12.5/mm³ with 70% polymorphs. Serum creatinine was 1.2 mg/dL.

The chest radiograph (postero-anterior view) was unremarkable. CT of the thorax with IV contrast (Figure 1) demonstrated narrowing of the lumen of the proximal left main bronchus. It showed circumferential, irregular contrast enhancing wall thickening. There were foci of air seen within the wall

[Received: August 17, 2012 accepted: November 9, 2012]

Correspondence and reprint requests: Dr Sandeep S. Tilve, Department of Respiratory Medicine, Lilavati Hospital, Mumbai (Maharashtra), India; E-mail: tilvesandeep@gmail.com

of the left main bronchus suggestive of dehiscence or ulceration in the bronchial wall. Mildly enlarged enhancing lymph nodes were evident in pre-tracheal, right para-tracheal, subcarinal and para-aortic regions. The lung parenchyma did not show any abnormality.

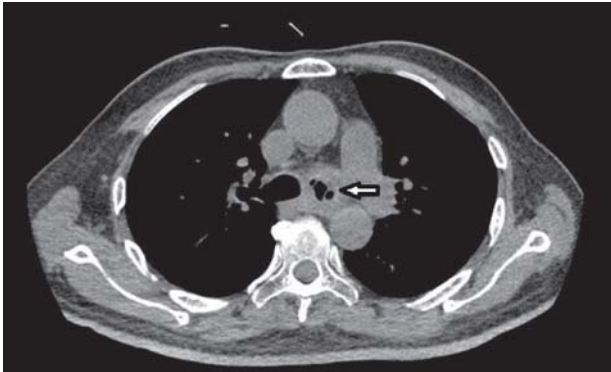


Figure 1. CECT of thorax showing pneumomediastinum, compressed left main bronchus (arrow) and bronchial wall thickening.

On fiberoptic bronchoscopy (FOB), carina was sharp; narrowing of the left main bronchus from the carina to secondary carina with irregular surface and nodularity was also seen. Rest of the left bronchial tree was normal. Right lower lobe bronchus mucosa was ulcerated with purulent secretions seen just below the middle lobe opening.

Bronchoalveolar lavage (BAL) fluid was collected and biopsies were obtained from the left main bronchial wall and from the ulcerative lesion on the right lower lobe bronchus wall.

Histopathological examination of the bronchial wall biopsy from the right lower lobe bronchus showed ulcerated mucosa and a piece of cartilage (Figure 2). The entire tissue was infiltrated by several septate fungal hyphae with dichotomous acute angle branching. Well-defined septae were evident in

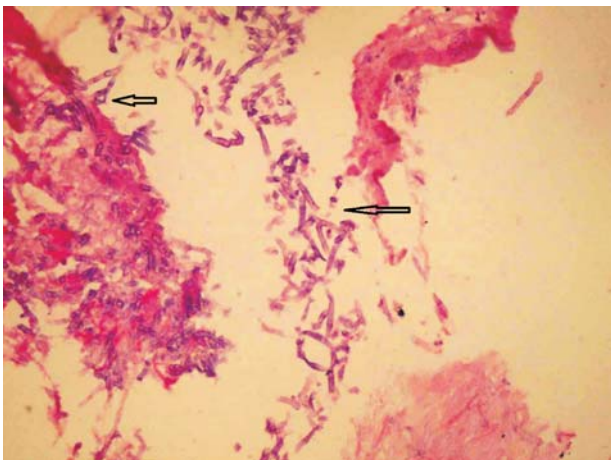


Figure 2. Photomicrograph showing of the biopsy material from right main bronchus showing dichotomously branching hyphae (arrows) invading in bronchial cartilage (Haematoxylin and eosin x100)

places. Fungi were seen to invade the cartilage and surrounding stroma. Focal squamous metaplasia was seen. Moderate to dense lymphocytic infiltrate with few neutrophils was seen in stroma suggestive of chronicity. The biopsy tissue from left main bronchus showed chronic inflammation only.

The BAL fluid was negative for acid-fast bacilli; Gram staining did not reveal any bacteria. Fungal staining showed septate hyphae. Culture of the fluid in special media showed growth of *Aspergillus fumigatus*.

Patient was started on voriconazole 200mg twice daily according to the Infectious Diseases Society of America (IDSA) guidelines.² After 15 days of starting voriconazole, the patient still had persistent cough and stridor and rhonchi were evident on bilateral lung fields on physical examination. Repeat CT of the thorax showed further narrowing of the left main bronchus.

FOB was repeated. The left main bronchus was further narrowed, right lower lobe bronchus was eroded; carinal involvement was also evident. The anteromedial surface of the left main bronchus showed fistulous opening suspected to be a broncho-oesophageal fistula. For confirmation, oesophagoscopy and barium swallow study were performed which, however, showed no evidence of any broncho-oesophageal fistula. The patient was started on intravenous caspofungin 70mg on first day followed by 50mg daily for 21 days. Voriconazole was continued in the same dosage. The patient improved clinically. Presently he is stable and taking oral voriconazole which he will be continuing to take for one year.

DISCUSSION

An immunocompromised patient presenting with chronic cough with normal plain radiograph raises the possibility of tracheobronchitis due to opportunistic infectious agents. Whereas tuberculosis (TB) tracheobronchitis and endobronchial TB are common causes in Indian scenario, airway invasive aspergillosis is a rare possibility. Invasive aspergillosis is a major cause of mortality in immunocompromised patients. Most cases of invasive aspergillosis present as angioinvasive form but less commonly of airway invasive form.¹ Inhalation of air borne *Aspergillus* spores result in colonisation of respiratory mucosal surfaces. The progression from colonisation to tissue invasion depends on the person's immune status and local defence mechanisms.³

The insidious presentation with nonspecific symptoms and paucity of findings on routine plain chest radiograph often delays the diagnosis. Patient usually presents with cough, dyspnoea, wheezing

and haemoptysis depending on the level of invasion. The diagnosis requires high index of suspicion due to rarity of the condition. CT of the thorax may appear normal in the early stages but in later stages it may show increased paratracheal or peribronchial shadow, narrowing of the tracheobronchial tree.¹ and pneumomediastinum.⁴ All these findings were present in the CT of the patient under discussion.

FOB allows direct visualisation of the lesions and facilitates confirmation of tissue diagnosis. Different morphological forms of the disease are described in the literature, namely, obstructive tracheobronchitis, pseudomembranous tracheobronchitis and ulcerative tracheobronchitis. It is possible that all these forms represent progressive spectrum of the disease.

Obstructive tracheobronchitis shows intraluminal growth of *Aspergillus* leading to obstruction which can cause atelectasis. Pseudomembranous tracheobronchitis is characterised by the formation of whitish pseudomembrane composed of hyphae, fibrin and necrotic debris. Attempt to remove the membrane may sometimes lead bleeding. The ulcerative form, which is rarest of the three^{4,5} shows ulcerative lesions may or may not be covered by debris. Deep ulcerative lesions sometimes may penetrate the bronchial wall leading to broncho-oesophageal fistula or broncho-arterial fistula that may cause fatal haemorrhage.^{6,7}

Bronchial biopsy specimen shows, acute and chronic inflammation, mucosal metaplasia and mild atypia. Ulcerated mucosal surface covered with necrotic material may be seen. Inflammatory cells are seen extending beyond submucosa gradually involving whole thickness of the bronchial wall. Narrow angle branching septate organisms can be seen penetrating the bronchial tissue on histopathological examination.

Once the diagnosis is established, the condition should be treated aggressively. The IDSA guidelines have recommended voriconazole 6mg/Kg body weight twice on day first followed by 4mg/Kg twice daily as the first-line treatment for *Aspergillus* tracheobronchitis. In some studies,^{8,9} a combination of caspofungin 70mg on day first followed by 50mg daily and voriconazole was associated with better outcomes and survival advantage.⁸⁻¹¹ The duration of therapy depends upon severity of the patient's underlying disease, recovery from immunosuppression, and clinical response. The median duration in various studies is 10 to 12 weeks. A

treatment for the duration of 6 months to 12 months may be required to eradicate the fungus.⁴ Our patient in discussion received the combination treatment for four months.

A locally invasive aspergillosis with ulcerative lesions with no parenchymal involvement is an important cause of tracheobronchitis in post-transplant patients. Early diagnosis and early treatment can improve the outcome. A combination treatment of caspofungin and voriconazole can be considered if patient not responding to voriconazole alone.

REFERENCES

1. Sancho JM, Ribera JM, Rosell A, Muñoz C, Feliu E. Unusual invasive bronchial aspergillosis in a patient with acute lymphoblastic leukemia. *Haematologica* 1997;82: 701-2.
2. Walsh T, Anaissie E. Treatment of aspergillosis: clinical practice guidelines of the Infectious Diseases Society of America. *Clin Infect Dis* 2008;46:327-60.
3. Clarke A, Skeleton J, Fraser RS. Fungal tracheo-bronchitis: report of 9 cases and review of the literature. *Medicine* 1991;70:1-14.
4. Ahn MI, Park SH, Kim JA, Kwon MS, Park YH. Pseudomembranous necrotizing bronchial aspergillosis. *Br J Radiol* 2000;73:73-5.
5. Kramer MR, Denning DW, Marshall SE, Ross DJ, Berry G, Lewiston NJ, et al. Ulcerative tracheobronchitis after lung transplantation: a new form of invasive aspergillosis. *Am Rev Respir Dis* 1991;144:552-6.
6. Patel N, Talwar A, Stanek A, Epstein M. Tracheobronchial pseudomembrane secondary to aspergillosis. *J Bronchol* 2006;13:147-50.
7. Putnam J, Dignani M, Mehra R, Anaissie E, Morice R, Libshitz H. Acute airway obstruction and necrotizing tracheobronchitis from invasive mycosis. *Chest* 1994;106: 1265-7.
8. Perea S, Gonzalez G, Fothergill AW, Kirkpatrick WR, Rinaldi MG, Patterson TF. In vitro interaction of caspofungin acetate with voriconazole against clinical isolates of *aspergillus* spp. *Antimicrob Agents Chemother* 2002;46:3039-41.
9. Wheat L. Combination antifungal therapy for aspergillosis: is it needed, and which combination? *J Infect Dis* 2003;187:1831-4.
10. Arikian S, Lozano-Chiu M, Paetznick V, Rex J. In vitro synergy of caspofungin and amphotericin B against *Aspergillus* and *Fusarium* spp. *Antimicrob Agents Chemother* 2002;46:245-7.
11. Kontoyiannis DP, Lewis RE. Combination chemotherapy for invasive fungal infections: what laboratory and clinical studies tell us so far. *Drug Resist Updat* 2003;6:257-69.