

Tuberculosis Lymphadenitis in a Well Managed Case of Sarcoidosis

P.R. Mohapatra, Kranti Garg, Niti Singhal, D. Aggarwal, R. Gupta, A. Khurana and A.K. Janmeja

Department of Pulmonary Medicine, Government Medical College and Hospital, Chandigarh, India

ABSTRACT

Differentiation between tuberculosis (TB) and sarcoidosis is sometimes extremely difficult. Sequential occurrence of sarcoidosis and TB in the same patient is uncommon. We present the case of a young man, with a proven diagnosis of sarcoidosis who later developed TB after completion of treatment for sarcoidosis. A 32-year-old male patient presented with low-grade fever since two months. Physical examination revealed cervical lymphadenopathy. Initial fine needle aspiration cytology (FNAC) of the cervical lymph node was suggestive of granulomatous inflammation; the chest radiograph was normal. Repeat FNAC from the same lymph node was suggestive of reactive lymphoid hyperplasia. The patient was treated with antibiotics and followed-up. He again presented with persistence of fever and lymphadenopathy and blurring of vision. Ophthalmological examination revealed uveitis, possibly due to a granulomatous cause. His repeat Mantoux test again was non-reactive; serum angiotensin converting enzyme (ACE) levels were raised. This time an excision biopsy of the lymph node was done which revealed discrete, non-caseating, reticulin rich granulomatous inflammation suggestive of sarcoidosis. The patient was treated with oral prednisolone and improved symptomatically. Subsequently, nearly nine months after completion of corticosteroid treatment, he presented with low-grade, intermittent fever and a lymph node enlargement in the right parotid region. FNAC from this lymph node showed caseating granulomatous inflammation and the stain for acid-fast bacilli was positive. He was treated with Category I DOTS under the Revised National Tuberculosis Control Programme and improved significantly. The present case highlights the need for further research into the aetiology of TB and sarcoidosis. [Indian J Chest Dis Allied Sci 2013;55:217-220]

Key words: Tuberculosis, Sarcoidosis, Lymph node, Acid-fast bacilli, Corticosteroid treatment.

INTRODUCTION

Sarcoidosis is a multi-system granulomatous disorder characterised by the presence of non-caseating granulomas in involved tissues. The aetiology and pathogenesis of sarcoidosis is still not settled despite medical advancement in understanding for years. The diagnosis of sarcoidosis rests on a constellation of clinical, radiological, histopathological, and laboratory data.¹ Because of the similarity of sarcoidosis to tuberculosis (TB) in both clinical presentation and histological features, a possible link between the two has been debated since long.² In a country like India, where there is a high prevalence of TB, sarcoidosis poses a greater challenge to clinicians and it is sometimes extremely difficult to differentiate between the two conditions. As the treatment for the two conditions is different, ascertaining the definitive diagnosis remains the key to management. However, co-existence of these two diseases has been described.³

CASE REPORT

A 32-year-old male patient presented with a chief complaint of low-grade fever since two months. Physical examination revealed a cervical lymph node on the right side which was 1cm×1cm in size, firm, non-tender and mobile. There was no other abnormality detected on physical examination. Laboratory investigations revealed haemoglobin 16 g/dL; total leukocyte count 10,000/mm³ with polymorphs 75%, lymphocytes 22%; blood urea 27 mg/dL; serum creatinine 1.3 mg/dL; total serum bilirubin 0.8 mg/dL. He was found to be non-reactive for human immunodeficiency virus (HIV) and Mantoux test showed no skin induration after 48 hours. Chest radiograph was within normal limits (Figure 1).

Fine needle aspiration cytology (FNAC) of the cervical lymph node showed few epithelioid granulomas and multi-nucleated giant cells in the background of reactive lymphoid cells. Staining for acid-fast bacilli (AFB) was negative. The FNAC was suggestive of granulomatous inflammation which could

[Received: 22, 2012; accepted after revision: October 22, 2013]

Correspondence and reprint requests: Dr Prasanta R. Mohapatra, Professor and Head, Department of Pulmonary Medicine, All India Institute of Medical Sciences, Sijua, Bhubaneswar-751 019 (Odisha), India; Phone: 09438884288, E-mail: prmohapatra@hotmail.com

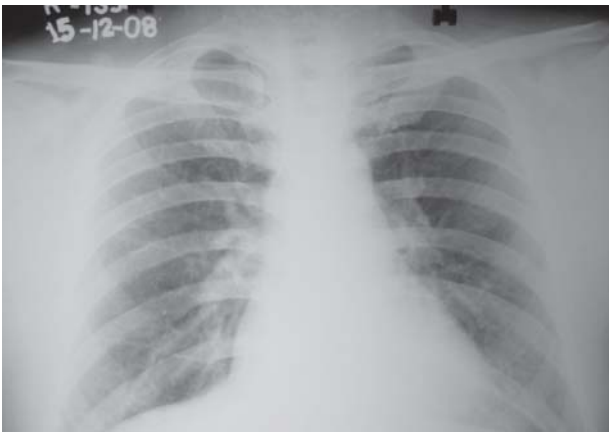

Figure 1. Chest radiograph (postero-anterior view) reported to be normal. This was obtained at the time the patient was diagnosed to have sarcoidosis based on excision biopsy of the cervical lymph node.

either be TB or sarcoidosis. The patient was advised to undergo a repeat FNAC examination of the cervical lymph node. The repeat FNAC showed polymorphic population of lymphoid cells in varying stages of maturation and no evidence of granulomatous inflammation suggestive of reactive lymphoid hyperplasia. The patient was treated with a course of antibiotics and was kept under a regular follow-up.

However, patient complained of persisting fever and the lymph nodes did not decrease in size. Patient started developing additional symptom of blurred vision. Ophthalmological examination revealed uveitis, likely due to a granulomatous cause. Repeat Mantoux test again was non-reactive but serum angiotensin converting enzyme (ACE) levels were raised (69 U/L). This time an excision biopsy of the lymph node was done and histopathological impression was suggestive of discrete, non-caseating, reticulin rich granulomatous inflammation favouring sarcoidosis (Figures 2A and 2B). The patient was treated with oral prednisolone 40 mg/day to start with. He showed significant clinical improvement in the form of regression of lymph nodes and improved vision. After two months, the prednisolone was gradually tapered off and then completely stopped after about one year.

Patient was completely asymptomatic for about nearly nine months after treatment completion. Subsequently, he complained of low-grade, intermittent fever and a lymph node enlargement in the right parotid region that was 2cm×1cm firm, non-tender and mobile. FNAC from this lymph node showed caseating granulomatous inflammation and the stain for AFB was positive (Figures 2C and 2D). Chest radiograph this time also was within normal

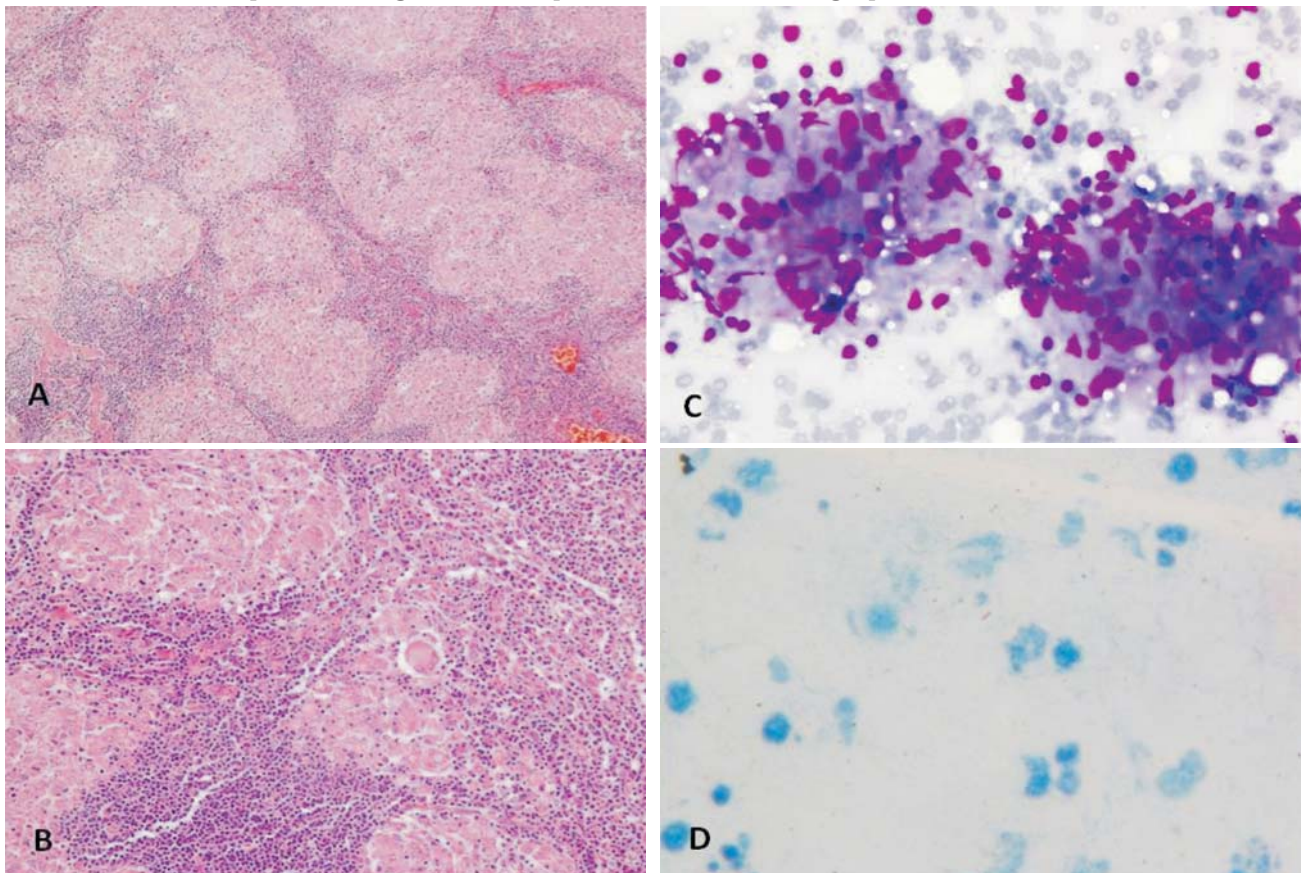


Figure 2. Photomicrograph showing multiple discrete non-caseating epithelioid granulomas and Langhans' giant cells (A) (Haematoxylin and eosinx100); (B) (Haematoxylin and eosinx200); granulomas composed of slipper shaped histiocytes and reactive lymphoid cells; (C) (May-Grunwald Giemsa stainx400); a single, beaded acid-fast bacillus (D) (Ziehl-Neelsenx1000).

limits (Figure 3). Thereafter, the patient was treated with thrice-weekly intermittent treatment Category I DOTS under the Revised National Tuberculosis Control Programme (RNTCP). The patient showed clinical improvement and the lymph node regressed completely. At one-year of follow-up, the patient remained asymptomatic with normal chest radiograph.

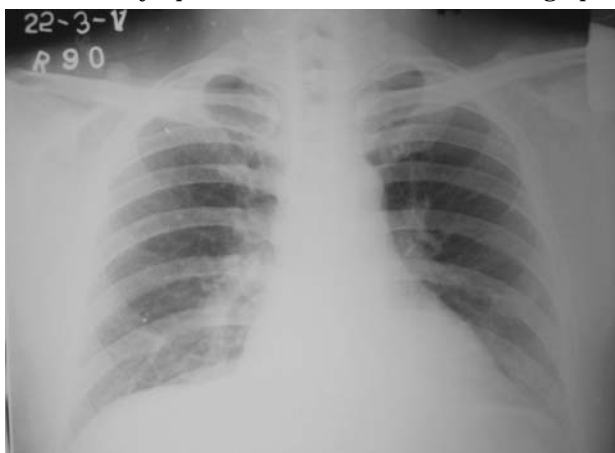

Figure 3. Chest radiograph (postero-anterior view) reported to be normal. This was obtained 3.4 years after the diagnosis of sarcoidosis when the patient was diagnosed to have smear positive TB lymphadenitis.

DISCUSSION

This young patient had both lymphatic and ocular involvement by sarcoidosis. He was first diagnosed as sarcoidosis on lymph node biopsy. Both the ocular and clinical symptoms disappeared on treatment with steroids. After a reasonable gap, he was diagnosed with TB lymphadenitis which was AFB positive. So it is reasonable to conclude that this patient to begin with had sarcoidosis who later on developed TB lymphadenitis. Sporadic case reports of the occurrence of sarcoidosis and TB in the same patient have been reported in the literature documenting either a concomitant or sequential occurrence of sarcoidosis followed by TB or vice versa.^{4,6}

Both infective and non-infective aetiologic agents have been incriminated as causative agents of sarcoidosis. *Mycobacterium tuberculosis* is one such infective agent.⁶ However, the inability to isolate mycobacteria by histological staining or culture from tissues in sarcoidosis continues to be one of the strongest arguments against a potential role for mycobacteria.³ Studies using polymerase chain reaction (PCR) have shown that the association does exist in a significant proportion of patients.⁷ These studies were done in populations with low prevalence of TB where chance of positivity due to contamination is very low. The possible role of TB in altering the behaviour of sarcoidosis or causing sarcoidosis in high prevalence country like India needs to be further explored.

There is a possibility that the index case had TB lymphadenitis from the beginning but the diagnosis could not be proven. The initial histopathological findings and other investigations supported the diagnosis of sarcoidosis, as mentioned above. This was further reconfirmed by resolution of patient's clinical and ocular symptoms with steroids. At that point, had the patient been harbouring TB lymphadenitis, his disease would have flared-up with the administration of corticosteroids. The subsequent occurrence of TB also could not be a result of immunosuppression due to corticosteroids, as the patient was asymptomatic for nearly nine months after the steroids were stopped.

The question which remains is whether the aetiologic agent of sarcoidosis in our patient was a cell wall deficient form of mycobacterial deoxyribonucleic acid (DNA) which later got converted to parent DNA form and caused TB. But had it been so, why did this conversion occur nearly two years after initial presentation as sarcoidosis? The perplexing questions which remain unanswered include: could sarcoidosis be an infectious disease or is it caused by unidentified mycobacteria with low virulence or is sarcoidosis an altered response to mycobacteria resulting in alterations of genome-wide gene expression possibly modified by gene-environment interactions? Recent studies have shown that the circulating immune cells in sarcoidosis possess significant alterations in genome-wide gene expression supporting a "systemic" inflammatory nature of sarcoidosis that challenges current thinking about the compartmentalisation of inflammation in sarcoidosis. Significant concordance in gene expression patterns between sarcoidosis and TB have been demonstrated, which provide vital clues for sarcoidosis aetiology.⁸ A recent study⁹ compared whole-blood gene expression profiling, micro ribonucleic acid (microRNA) expression, and multiplex serum analytes of TB and sarcoidosis. Their analysis reveals the gene expression signatures in TB show highly similar patterns in sarcoidosis, with a common up-regulation of proinflammatory pathways and interferon signalling and close similarity to TB signatures. The microRNA expression also shown a highly similar pattern in both, whereas cytokines in the serum of TB patients revealed a slightly elevated proinflammatory pattern compared with sarcoidosis and controls.⁹

Therefore, we feel that in the current case, it is unlikely that both the granulomatous pathologies were independent of each other. Why the initial manifestation was with sarcoidosis (in a country where TB is very common) is still not clear. The subsequent occurrence of TB lymphadenitis (rather than pulmonary TB) in this patient (who had sarcoidosis of the lymph node) requires further research in understanding the aetiopathogenesis of TB and sarcoidosis.

REFERENCES

1. Jindal SK, Gupta D, Aggarwal AN. Sarcoidosis in India: practical issues and difficulties in diagnosis and management. *Sarcoidosis Vasc Diffuse Lung Dis* 2002;19: 176-84.
2. Sharma OP. Murray Kornfeld, American College of Chest Physicians and sarcoidosis: a historical footnote. 2004 Murray Kornfeld Memorial Founders Lecture. *Chest* 2005;128:1830-5.
3. Gupta D. Tuberculosis and sarcoidosis: the continuing enigma. *Lung India* 2009;26:1-2.
4. Papaetis GS, Pefanis A, Solomon S, Tsangarakis I, Orphanidou D, Achimastos A. Asymptomatic stage I sarcoidosis complicated by pulmonary tuberculosis: a case report. *J Med Case Reports* 2008;2:226.
5. Baughman RP. Can tuberculosis cause sarcoidosis? New techniques try to answer an old question. *Chest* 1998;114: 363-4.
6. Drake WP, Newman LS. Mycobacterial antigens may be important in sarcoidosis pathogenesis. *Curr Opin Pulm Med* 2006;12:359-63.
7. Jindal SK. Mycobacterial relationship of sarcoidosis: the debate continues. *Expert Rev Respir Med* 2008;2:139-43.
8. Koth LL, Solberg OD, Peng JC, Bhakta NR, Nguyen CP, Woodruff PG. Sarcoidosis blood transcriptome reflects lung inflammation and overlaps with tuberculosis. *Am J Respir Crit Care Med* 2011;184:1153-63.
9. Maertzdorf J, Weiner J, 3rd, Mollenkopf HJ, Network T, Bauer T, Prasse A, *et al*. Common patterns and disease-related signatures in tuberculosis and sarcoidosis. *Proc Natl Acad Sci USA* 2012;109:7853-8.