

# Giant Chondrosarcoma of Chest Wall

Kaushik Mukherjee, Madhusudan Pal, Enakshi Saha, Niranjana Maity, Suranjan Halder and Rajarshi Ghosh

Department of Cardiothoracic and Vascular Surgery, Medical College Hospital, Kolkata (West Bengal), India

---

## ABSTRACT

---

Primary chest wall tumours are very rare. Chondrosarcoma is the most common tumour arising from the chest wall. We describe the occurrence of a slow-growing chondrosarcoma arising from the anterior chest wall in a 35-year-old male patient. The tumour was resected successfully and chest wall was reconstructed with prolene mesh and muscle flap. The patient was discharged uneventfully without any respiratory compromise. There was no recurrence after a three-year follow-up. Wide surgical resection with chest wall reconstruction appears to be the preferred treatment option for this rare tumour of the chest wall. [Indian J Chest Dis Allied Sci 2013;55:229-231]

**Key words:** Tumour, Chondrosarcoma; Chest wall reconstruction.

---

## INTRODUCTION

---

Primary chest wall tumours are uncommon.<sup>1</sup> Chondrosarcoma is the most common neoplasm of the anterior chest wall, representing 20% to 30% of the primary tumours of the thoracic wall. Eighty percent of these originate from the cartilaginous and bony structures of ribs and 20% originate from the sternum.<sup>2-4</sup> Chest wall chondrosarcomas rarely present as an anterior mediastinal mass.<sup>5</sup> Most of these tumours arise from the costochondral or the chondrosternal junction. This tumour occurs more often during the third and fourth decade of life; males are more commonly affected. Chest wall tumours grow slowly. Median survival for these tumours is 2.5% and overall survival is 46%.<sup>6</sup> Result of resection of these tumours yields better outcomes when measures were taken to reconstruct the chest wall defect which is created after the tumour has been removed.

---

## CASE REPORT

---

A 35-year-old male patient presented with a slow-growing mass in front of his left chest wall for the last 10 years. The mass had an irregular surface and ill-defined margins. It was measuring 20cmx15cm, was hard and fixed to the anterior left chest wall (Figure 1). Chest radiograph showed a soft tissue shadow on the left chest wall. Contrast enhanced computed tomography (CECT) of the chest revealed a large heterogeneous lobulated mass on the left

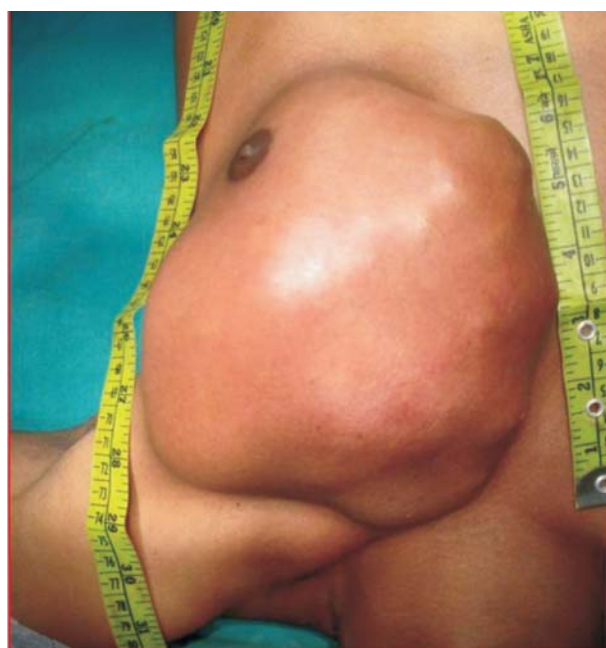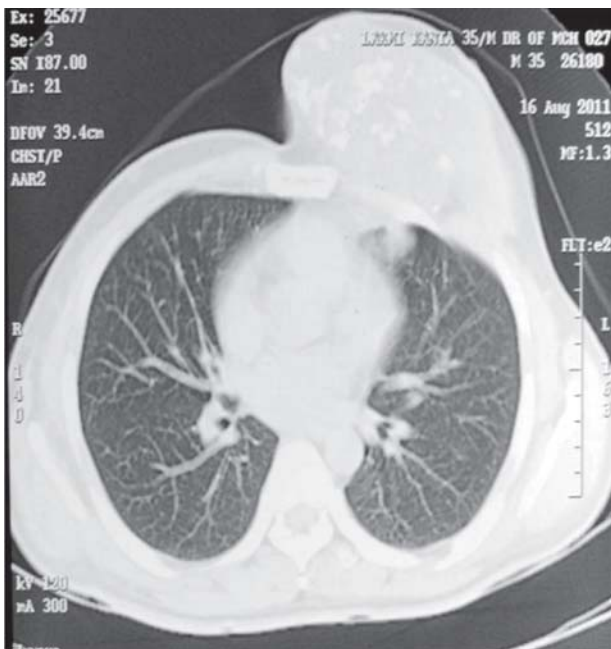


Figure 1. Clinical photograph showing a tumour in the anterior chest wall.

anterior chest wall (Figure 2). Fine needle aspiration cytology (FNAC) from the mass was consistent with a slow-growing tumour showing round cells with eosinophilic vacuolated cytoplasm in a chondromyxoid background. Wide local excision of the mass was done with adequate margin including anterior parts of 4<sup>th</sup>, 5<sup>th</sup> and 6<sup>th</sup> ribs up to chondrosternal junction.

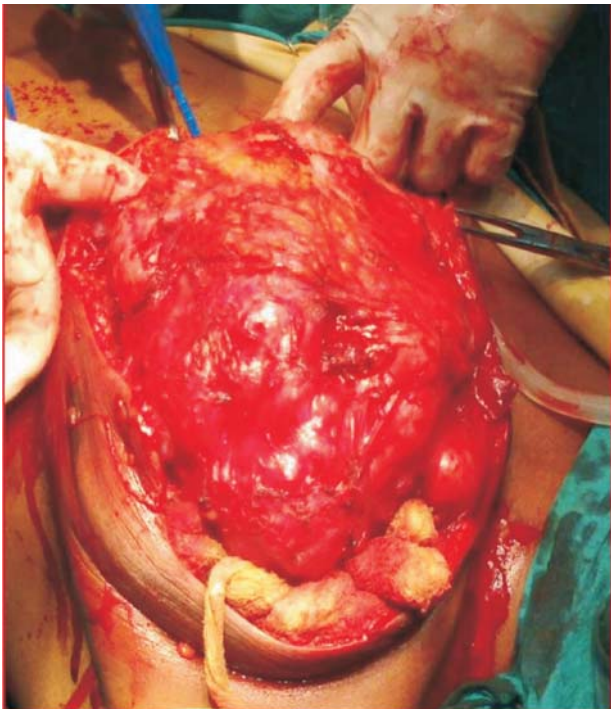
[Received: July 2, 2012; accepted after revision: October 26, 2012]

**Correspondence and reprint requests:** Dr Kaushik Mukherjee, Assistant Professor, Department of Cardiothoracic and Vascular Surgery, Medical College Hospital, Kolkata (West Bengal), India; Phone: 91-08420966115; E-mail: drmukherjeekaushik@yahoo.com

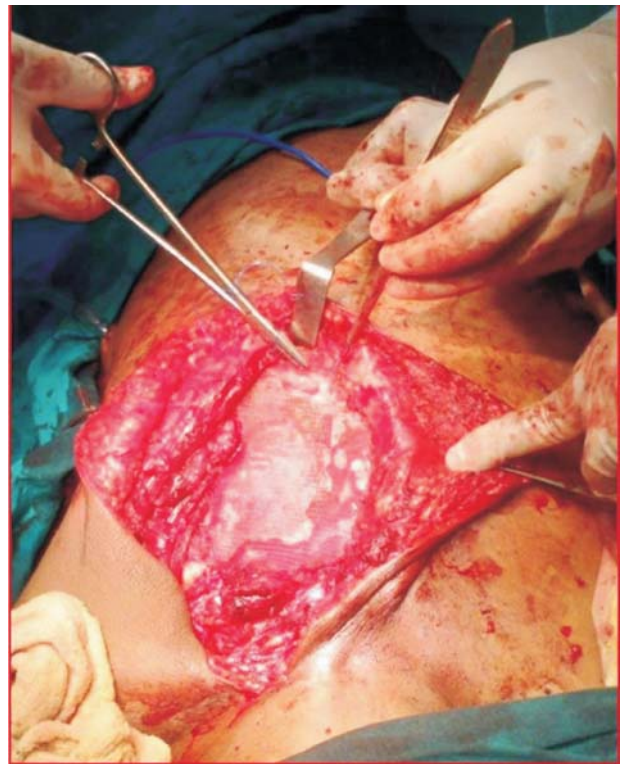

**Figure 2.** CECT of the chest (sagittal reconstruction) showing a large heterogeneous lobulated mass on the left anterior chest wall.

Chest wall defect was reconstructed with polypropylene mesh and reinforced with pectoralis major and latissimus dorsi flaps of same side (Figures 3 and 4). Post-operative stay was uneventful and histopathology of the excised tumour confirmed chondrosarcoma grade II. After three years follow-up, the patient is doing well with no sign of local recurrence.



**Figure 3.** Intra-operative photograph showing the dissected mass.



**Figure 4.** Intra-operative photograph showing prolene mesh reconstruction of the chest wall.

## DISCUSSION

Chondrosarcomas are lobulated tumours that may grow to massive proportions and, consequently, may extend internally to the pleural space, or externally, invading muscle, adipose tissue and skin of the thoracic wall. The patients generally present with consistent slow-growing mass for several months. Microscopically, the findings vary from normal cartilage to obvious malignant modifications. The differentiation between chondroma and chondrosarcoma can be extremely difficult.<sup>7</sup> Palpable mass in thorax is the main symptom in approximately 80% of the patients with thoracic wall tumour. Of these, 60% present with associated pain.<sup>2</sup> Computed tomography (CT) and magnetic resonance imaging (MRI) are useful to characterise the tumour and its extension. CT is superior to MRI in demonstrating calcification, whereas MRI is the imaging modality of choice to evaluate the tumour extension and its relationship with adjacent structures.<sup>8-12</sup> The purpose of the first surgery must be a wide resection, enough to prevent local recurrence. This means obtaining wide margins at the time of initial resection (4cm margin at each side).<sup>13,14</sup> The recurrence rate for patients with adequate surgical margins was 10%, compared with 75% for patients with inadequate margins.<sup>15</sup> Overall and local recurrence free survival in chondrosarcoma of the chest wall depends: (i) low grade tumour, (ii) bone invasion; and (iii) associated

sternal resection. The 5-year survival rate for patients with adequate surgical margins was 100%, compared with 50% in patients with inadequate surgical margins. Local recurrence-free survival is around 64%.<sup>6</sup> An inadequate margin of resection was associated with a significantly worse overall survival and a higher chance of having local recurrence develop.<sup>15</sup> On multivariable analysis, prognostic factors for local recurrence included surgical margin and histological grade; prognostic factors for metastases included histologic grade, tumour size, and occurrence of local recurrence.<sup>16</sup> There was a remarkable case report of a patient<sup>17</sup> who was treated by multiple (six times) surgical procedures including left costo-pleuro-pneumonectomy and left subclavian artery end-to-end anastomosis between 1998 and 2005. Despite the palliative character of surgery, he achieved long-term survival but finally refused next surgery due to the risk of left upper limb amputation and died a few months later.<sup>17</sup> Use of prosthetic mesh and myocutaneous flap is good method for stabilisation of the chest wall and is helpful in avoiding paradoxical respiratory movements.

---

## REFERENCES

---

1. Liptay MJ, Fry WA. Malignant bone tumors of the chest wall. *Semin Thorac Cardiovasc Surg* 1999;11:278-84.
2. Vaporciyan AA, Swisher SG. Thoracic malignancies. In: Feig BW, Berger DH, Fuhrman GM, editors *The M.D. Anderson Surgical Oncology Handbook*; 2nd edition. Philadelphia: Lippincott Williams & Wilkins; 1999:pp109-29.
3. Dahlin DC, Unni KK. *Bone Tumors: General Aspects and Data on 8,542 Cases*. Springfield: Thomas;1986.
4. Somers J, Faber LP. Chondroma and chondrosarcoma. *Semin Thorac Cardiovasc Surg* 1999;11:270-7.
5. Mhandu P, Chaubey S, Khan H, Deshpande R. Unusual presentation of a chondrosarcoma as an anterior mediastinal mass. *J Surg Case Report* 2012;4:1.
6. van Geel A, Wouters M, Lans T, Schmitz P, Verhoef C. Chest wall resection for adult soft tissue sarcomas and chondrosarcomas: analysis of prognostic factors. *World J Surg* 2011;35:63-9.
7. Pairolero P. Chest wall tumors. In: Shields TW, editor *General Thoracic Surgery*; 4th edition. Baltimore: Williams & Wilkins; 1994:pp579-88.
8. Parham FW. Thoracic resection for tumor growing from the bony wall of the chest. *Trans Surg Gynecol Assoc* 1898; 11:223-63.
9. Fraser RS. The chest wall. In: Fraser RS, Miller NZ, Colman N, Paré PD, editors *Fraser and Paré's Diagnosis of Diseases of the Chest*; 4th edition. Philadelphia: W.B. Saunders; 1999:pp3030-2.
10. Albes JM, Seemann MD, Heinemann MK, Ziemer G. Correction of anterior thoracic wall deformities: improved planning by means of 3D-spiral-computed tomography. *Thorac Cardiovasc Surg* 2001;49:41-4.
11. Gefter WB. Magnetic resonance imaging in the evaluation of lung cancer. *Semin Roentgenol* 1990;25:73-84.
12. Tang A, Dalrymple-Hay M, Weeden D. Images in cardiothoracic surgery: giant chondrosarcoma of the anterior chest wall. *Eur J Cardiothorac Surg* 2000;17:84.
13. O'Sullivan P, O'Dwyer H, Flint J, Munk PL, Muller NL. Malignant chest wall neoplasms of bone and cartilage: a pictorial review of CT and MR findings. *Br J Radiol* 2007; 80:678-84.
14. Yokote K, Osada H. Indication and method of chest wall reconstruction. *Kyobu Geka* 1996;49:38-41.
15. Fong YC, Pairolero PC, Sim FH, Cha SS, Blanchard CL, Scully SP. Chondrosarcoma of the chest wall: a retrospective clinical analysis. *Clin Orthopaed Relate Res* 2004;427:184-9.
16. Widhe B, Bauer HC. Surgical treatment is decisive for outcome in chondrosarcoma of the chest wall: a population based Scandinavian sarcoma group study of 106 patients. *J Thorac Cardiovasc Surg* 2009;137:610-4.
17. Grodzki T, Wójcik J, Pieróg J, Kubisa B. Long-term survival after resection of giant chondrosarcoma of the chest wall weighing 9.6 kg. *Eur J Cardiothorac Surg* 2007;32:394-6.