

## Case Report

# Primary Pulmonary Diffuse Large B-Cell Non-Hodgkin's Lymphoma in a Child

Arathi Srinivasan<sup>1</sup>, Thangadorai Ravikumar<sup>2</sup>, Appaswamy Andal<sup>2</sup> and Julius Xavier Scott<sup>1</sup>

Departments of Pediatric Hemato-oncology<sup>1</sup>, and Pediatrics<sup>2</sup>, Kanchi Kamakoti CHILDS Trust Hospital and CHILDS Trust Medical Research Foundation, Chennai, India

## ABSTRACT

A 3-year-old girl presented with a history of intermittent fever of six months duration associated with respiratory symptoms consisting of recurrent cough, fever, wheeze and a suspected history of contact with tuberculosis (TB). Chest radiograph revealed pulmonary infiltrates mimicking miliary TB. She was started on anti-tuberculous treatment, but in view of clinical deterioration, a further work-up including a lung biopsy revealed non-Hodgkin's lymphoma (NHL). This case documents the extremely rare occurrence of pulmonary involvement and miliary infiltrates on the chest radiograph in NHL. [Indian J Chest Dis Allied Sci 2013;55:225-227]

**Key words:** Miliary infiltrates, Diffuse large cell lymphoma, Children.

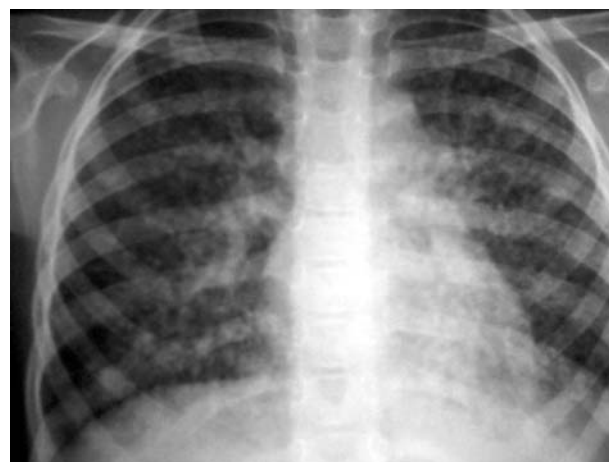
## INTRODUCTION

Non-Hodgkins lymphoma (NHL), particularly diffuse large B-cell lymphoma, presents commonly as tumours in abdomen. Pulmonary involvement of lymphoma is extremely rare. The pulmonary involvement of NHL are usually nodular type or bronchovascular-lymphangitic type.<sup>1</sup> Miliary infiltrates in NHL are extremely rare. Involvement of the lung with the lymphomatous process occurs in 5% to 20% of patients at diagnosis and eventually in 20% to 60%.<sup>2</sup> We report the case of a 3-year-old girl who presented with pulmonary infiltrates mimicking miliary tuberculosis (TB) who was later diagnosed to have diffuse large B-cell NHL of the lung.

## CASE REPORT

A 3-year-old girl presented with a history of intermittent fever of six months duration associated with respiratory symptoms, like recurrent cough, fever and wheeze. There was no history of contact with TB. Preliminary work-up for TB which included erythrocyte sedimentation rate, Mantoux test, chest radiograph, gastric juice for acid-fast bacilli were negative. She was started on treatment for reactive airway disease. One year later, when she presented with fever and respiratory symptoms like cough

and wheezing. Physical examination revealed hepatomegaly (3cm below the right costal margin) and splenomegaly (5cm below left costal margin). Respiratory system examination revealed bilateral diffuse crepitations. Complete blood counts showed neutrophilic leucocytosis. Chest radiograph at this time showed miliary infiltrates (Figure 1). She was treated initially with antibiotics. Parents did not agree



**Figure 1.** Chest radiograph (postero-anterior view) showing diffuse bilateral miliary infiltrates.

for a bronchoalveolar lavage (BAL) or lung biopsy. In view of the presence of miliary mottling on chest radiograph, although there was no other evidence for

[Received: March 30, 2012; accepted after revision: October 22, 2012]

**Correspondence and reprint requests:** Dr Julius Xavier Scott, Senior Consultant, Department of Pediatric Hemato-oncology, Kanchi Kamakoti CHILDS Trust Hospital and CHILDS Trust Medical Research Foundation, No 12-A, Nageswara Road, Nungambakkam, Chennai-600 034 (Tamil Nadu), India; Phone : 09488286303 (Off.): 91-44-42001800; Fax: 91-44-28259633; E-mail: jxscott@hotmail.com

TB, she was started on anti-tuberculosis treatment (ATT) with a four drug regimen (isoniazid: 10mg/kg, rifampicin: 10mg/kg, pyrazinamide: 25mg/kg and ethambutol: 30mg/kg). Six months later, while still receiving ATT, she presented once again with persistent cough and progressive respiratory distress. Physical examination revealed persistence of the hepatosplenomegaly and crepitations on chest examination. Blood counts revealed leucocytosis ( $40,400/\text{mm}^3$ ), neutrophilia and raised C-reactive protein (96mg/dL). Chest radiograph at this time showed worsening with evidence of bilateral pulmonary infiltrates. Serum immunoglobulin levels were normal. High-resolution computed tomography (HRCT) revealed bilateral diffuse pulmonary infiltrates (Figure 2). BAL fluid analysis was negative for TB and other infections. Bone marrow aspiration was reported to be normal. In view of persistent symptoms, she underwent thoracoscopic lung biopsy which revealed NHL (diffuse large B-cell lymphoma). Ultrasonography of the abdomen showed hepatosplenomegaly. Cerebrospinal fluid analysis was normal. Positron emission tomography (PET) scan could not be done in view of financial constraints.

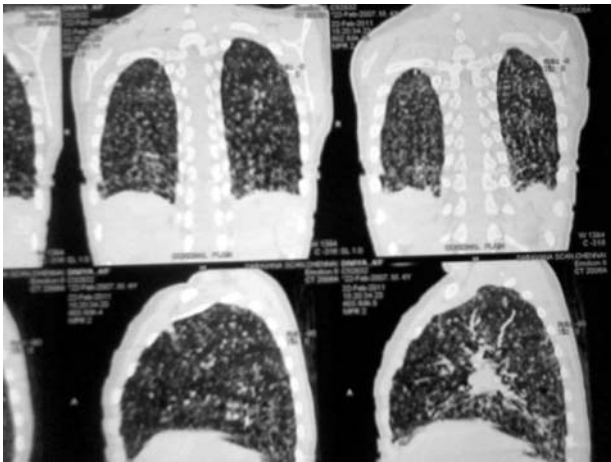


Figure 2. HRCT chest showing diffuse miliary infiltrates.

She was started on chemotherapy as per the protocol (LymphomesMalins B-96[LMB-96] after risk stratification as group B. After initial cyclophosphamide, vincristine, prednisolone (COP) reduction, chest radiograph showed complete clearance of the pulmonary infiltrates (Figure 3).

After four cycles of chemotherapy (COP, COPADM1, (Cyclophosphamide, Vincristine [oncovin], Prednisolone, Doxorubicin [Adriamycin], Methotrexate) COPADM2, and CYM1(Cytarabine, Methotrexate), she showed a good response without any active lesions. She has completed CYM2 and thereby a total of five cycles as per group B based therapy of LMB 96 Protocol. A repeat chest radiograph after completion of therapy was normal. She is currently under follow-up for last six months and is doing well.

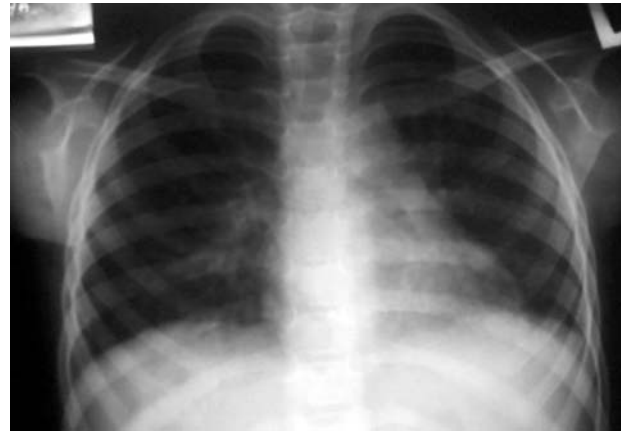

Figure 3. Repeat chest radiograph (postero-anterior view) after COP reduction showing resolution of miliary infiltrates. COP=Cyclophosphamide, vincristine, prednisolone

## DISCUSSION

The term "miliary" describes the radiographic picture of diffuse, discrete nodular shadows about the size of a millet seed (2mm). Most common cause of miliary mottling in a chest radiograph in India is miliary TB. Tropical pulmonary eosinophilia, varicella pneumonia, haemosiderosis, sarcoidosis, infections like toxoplasmosis, syphilis are other causes of miliary mottling which are seen infrequently. Other causes of miliary mottling, such as metastases, histiocytosis, Gauchers disease are very rare.<sup>3</sup>

Pulmonary involvement of lymphoma is extremely rare. Primary pulmonary NHL is very rare and accounts 0.4% of all lymphomas. The pulmonary involvement of NHL can be classified as nodular type, bronchovascular-lymphangitic type. The radiographic appearance of lung involvement in malignant lymphoma includes: (i) one or more areas of pulmonary consolidation resembling pneumonia; (ii) multiple nodules; and (iii) occasionally, miliary nodulation or reticulonodular shadowing.<sup>4</sup>

Diffuse large B-cell lymphoma occurs only in 10% cases of primary pulmonary NHL.<sup>5</sup> Our patient presented with diffuse pulmonary infiltrates mimicking miliary TB and hence received anti-TB treatment which has been a reason for delay in the diagnosis. The diagnosis of diffuse large B cell lymphoma was evident on lung biopsy only done in view of the progression of symptoms and inadequate response to ATT.

Recent literature reports a case of primary pulmonary diffuse large B-cell lymphoma presenting with bilateral, interstitial pulmonary involvement.<sup>6</sup> A case of NHL presenting with miliary infiltrates in a 60-year-old patient has been documented.<sup>7</sup> The authors<sup>7</sup> suggested that miliary infiltrates of NHL might represent a rapid progression of lymphoma cells and may be a poor prognostic sign. In another case report,<sup>8</sup> presentation of diffuse large B-cell

lymphoma as multiple pulmonary nodules with consolidation in a 50-year-old man was observed. In other reports, anaplastic large cell lymphoma with pulmonary presentation mimicking miliary TB;<sup>9</sup> and with diffuse pulmonary infiltrates<sup>10</sup> have been documented. *To the best of our knowledge, so far no cases of primary diffuse large B cell lymphoma presenting as miliary infiltrates in lung have been reported in children.*

The appearance of similar chest lesions during therapy also poses diagnostic and management problems. The underlying impaired immunity along with aggressive therapy results in pulmonary complications like infections and cytotoxic drug-induced pneumonitis. BAL has proved to be an extremely effective method for rapid diagnosis of many pulmonary infections in the immunocompromised host.<sup>2</sup> The prevalence of parenchymal pulmonary lesions in lymphoma in children has been observed to be 13% and all of them needed a biopsy for definitive diagnosis.<sup>11</sup>

Patients with relapsed or primary refractory diffuse large B-cell lymphoma who achieve complete response before autologous stem-cell transplantation generally have better outcomes than those who achieve only partial response. Rituximab with ifosfamide-carboplatin-etoposide chemotherapy regimen has been used to enhance the remission rates in such children.<sup>12</sup>

The present case highlights the importance of ascertaining tissue diagnosis rather than instituting empirical anti-TB treatment. Though most common cause for miliary mottling is TB in developing countries like India, rare possibility of B-Type NHL should be considered especially when there is no microbiological evidence of TB or if there is no expected response.

---

## REFERENCES

---

1. Balikian JP, Herman PG. Non-Hodgkin lymphoma of the lungs. *Radiology* 1979;132:569.
2. Campbell JH, Raina V, Banham SW, Cunningham D, Soukop M. Pulmonary infiltrates: diagnostic problems in lymphoma. *Postgrad Med J* 1989;65:881-4.
3. Willich E, Richter E. The thorax (upper respiratory tract, lungs, hilum, pleura, chest wall, diaphragm). In: Ebel KD, Blickman J, Willich E, Richter E, editors *Differential Diagnosis in Pediatric Radiology*; 1st edition. New York: Thieme; 1999:pp1-151.
4. Armitage JO, Weisenburger DD. New approach to classifying non-Hodgkin's lymphomas: clinical features of the major histologic subtypes. Non-Hodgkins Lymphoma Classification Project. *J Clin Oncol* 1998;16:2780-95.
5. Zinzani PL, Martelli M, Poletti V, Vitolo U, Gobbi PG, Chisesi T, et al; and Italian Society of Hematology; Italian Society of Experimental Hematology; Italian Group for Bone Marrow Transplantation. Practice guidelines for the management of extranodal non-Hodgkin's lymphomas of adult non-immunodeficient patients. Part I: Primary lung and mediastinal lymphomas. *Haematologica* 2008;93:1364-71.
6. Wrobel T, Dzietczenia J, Sobieszek MP, Mazur G, Piwkowski P. Primary pulmonary diffuse large B-cell lymphoma. *Am J Hematol* 2012;87:107-8.
7. Miyake S, Yoshizawa Y, Ohkouchi Y, Kurashima A, Hebisawa A. Non-Hodgkin's lymphoma with pulmonary infiltrates mimicking miliary tuberculosis. *Intern Med* 1997;36:420-3.
8. Liang W, Feng S, Li Z, Chen J. Pulmonary involvement by diffuse large B cell lymphoma: a case report and review of the literatures. *U.S. Chinese J Lymphol Oncol* 2007;6:17-9.
9. Close PM, Macrae MB, Hammond JM, Aronson I, Johnson CA, Potgieter PD, et al. Anaplastic large-cell Ki-1 lymphoma: pulmonary presentation mimicking miliary tuberculosis. *Am J Clin Pathol* 1993;99:631-6.
10. Onciu M, Behm FG, Raimondi SC, Moore S, Harwood EL, Pui CH, et al. ALK-positive anaplastic large cell lymphoma with leukemic peripheral blood involvement is a clinicopathologic entity with an unfavorable prognosis: report of three cases and review of the literature. *Am J Clin Pathol* 2003;120:617-25.
11. Maturen KE, Blane CE, Strouse PJ, Fitzgerald JT. Pulmonary involvement in pediatric lymphoma. *Pediatr Radiol* 2004;34:120-4.
12. Kewalramani T, Zelenetz AD, Nimer SD, Portlock C, Straus D, Noy A, et al. Rituximab and ICE as second-line therapy before autologous stem cell transplantation for relapsed or primary refractory diffuse large B-cell lymphoma. *Blood* 2004;103:3684-8.