

Spontaneous Oesophago-Pleural Fistula

Ramakant Dixit¹, Nishtha Singh¹ and Avinash Gupta²

Departments of Respiratory Medicine and Tuberculosis¹ and Radiodiagnosis², J.L.N. Medical College, Ajmer (Rajasthan), India

[Indian J Chest Dis Allied Sci 2014;56:173-174]

Case Summary

A 54-year-old male presented with acute onset breathlessness and left-sided chest pain of three days duration. He also had slight difficulty in deglutition for the last two days. These symptoms appeared following an episode of sudden onset of nausea and projectile vomiting after heavy meal and had progressively increased over the next two days. There was no history of fever, cough, palpitation, syncope, trauma or any history of undergoing diagnostic procedures. The past medical history was negative for any medical illness or hospitalisation. He was non-smoker and non-alcoholic.

On examination, pulse was 110/min, blood pressure was 130/80mmHg and respiratory rate was 24/min. Mild surgical emphysema was evident in the chest wall and neck. Rest of the general physical examination was unremarkable. On respiratory system examination, reduced thoracic movements, reduced vocal fremitus, dull percussion note, reduced intensity of breath sounds were evident on both sides but were more prominent on the left side. Further, crepitations and rhonchi were also present on the left side. Rest of the systemic examination was unremarkable.

Investigations

His complete blood count, haemogram and biochemical tests were within normal limits. Electrocardiogram (ECG) revealed sinus tachycardia; no ST-T changes were seen. Chest radiograph (Figure 1) showed hydropneumothorax on the left side with pleural effusion on the right side. Pleural fluid analysis was as follows: protein content 1.24 g/dL, glucose 74.5 gm%, chloride 84.3 mEq/L, cell count 1500/mm³ (polymorphs 50%, lymphocytes 50%) and adenosine deaminase (ADA) 46 IU/L.

Broad-spectrum antibiotics were initiated and closed tube thoracostomy was performed on the left side. Subsequent chest radiograph showed expansion of left lung with drainage of effusion but an increase in pleural effusion on the right side. Radiograph barium swallow showed abnormal extravasation of the barium and passage of contrast into the pleural space

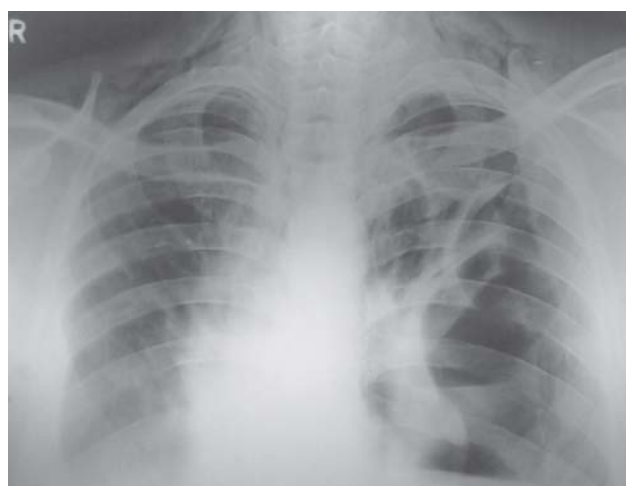

Figure 1. Chest radiograph (postero-anterior view) showing hydropneumothorax on the left side, pleural effusion on the right side and subcutaneous emphysema.

(Figure 2). It was also observed that food particles and swallowed liquids (e.g., milk) were partly draining through the chest tube. The patient was immediately referred to thoracic surgical unit at higher centre for further management. He was lost to follow-up thereafter.

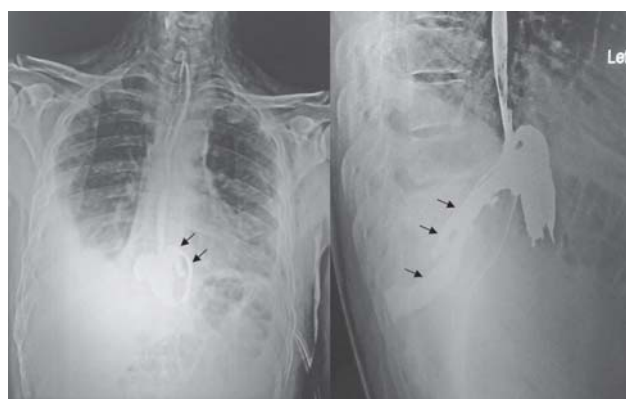


Figure 2. Radiograph barium swallow (PA and lateral views) showing abnormal extravasations of the contrast into pleural space (arrows).

Diagnosis: Spontaneous oesophago-pleural fistula following forceful vomiting (Boerhaave's syndrome).

[Received: May 13, 2013; accepted after revision: November 26, 2013]

Correspondence and reprint requests: Dr Ramakant Dixit, Associate Professor, A-60, Chandravarai Nagar, Ajmer-305 001 (Rajasthan), India; E-mail: dr.ramakantdixit@gmail.com

Discussion

Boerhaave's syndrome is an uncommon cause of oesophageal rupture characterised by spontaneous full-thickness oesophageal perforation. It usually results from a sudden rise in the intra-oesophageal pressure secondary to contraction of cricopharyngeus muscle and closing of pyloric sphincter that occurs after forceful vomiting. Patients with Boerhaave's syndrome classically present with vomiting, subcutaneous emphysema and lower thoracic pain (Mackler triad).¹ This syndrome is uncommon and accounts for approximately 15% of traumatic oesophageal perforations.^{2,3}

The symptoms and clinical signs of oesophago-pleural fistula are non-specific. Chest radiograph may show pleural effusion, pneumothorax, hydropneumothorax, subcutaneous emphysema or pneumomediastinum depending upon the site, duration, severity of perforation and integrity of the pleura. The contrast study of oesophagus using barium is very useful in lower oesophageal perforation and passage of oral contrast into the pleural space confirms the diagnosis of oesophago-pleural fistula. Other investigations that help in the diagnosis include thoracic ultrasonography, computed tomography, magnetic resonance imaging, upper gastrointestinal endoscopy among others.⁴

Management of this condition depends upon the site, size, duration of injury and the extent of mediastinal involvement. Conservative therapy includes drainage of empyema, local irrigation, tube feeding, gastrostomy or jejunostomy. Primary repair is the treatment of choice and should preferably be done within 24 hours. Other measures include cervical oesophagostomy, T-tube placement and plastic covered self expandible metallic stents, etc.⁵

The Boerhaave's syndrome should be differentiated from Mallory-Weiss syndrome that is characterised by longitudinal mucosal lacerations caused by forceful or long-term retching, vomiting or coughing. These

patients present with gastrointestinal bleeding; the oesophageal mucosal tears heal spontaneously. This condition is commonly associated with hiatus hernia and alcoholism.⁶

Oesophago-pleural fistula may occur secondary to the iatrogenic trauma (endoscopy and allied procedures), barotraumas, following empyema thoracis, oesophageal malignancy, tuberculosis, corrosive oesophagitis, oesophageal ulcers, surgical procedures (especially, post-pneumonectomy) and radiation therapy.^{7,8}

The clinical presentation may mimic aspiration pneumonia, lung abscess, pneumothorax, pulmonary embolism, myocardial infarction, aortic dissection, pericarditis, acute gastritis, acute pancreatitis and acute cholecystitis. Boerhaave's syndrome is an uncommon and a dangerous entity. Rapid diagnosis and early institution of therapy provides the best chance of survival.

References

1. Yagnik VD. Boerhaave's syndrome: spontaneous full thickness oesophageal perforation. *Lung India* 2012;29:197.
2. Jagminas L, Silverman RA. Boerhaave's syndrome presenting with abdominal pain and right hydropneumothorax. *Am J Emerg Med* 1996;14:53-6.
3. Giménez A, Franquet T, Erasmus JJ, Martínez S, Estrada P. Thoracic complications of esophageal disorders. *Radio Graphics* 2002;22:S247-58.
4. Wechsler RJ. CT of esophageal-pleural fistulae. *AJR Am J Roentgenol* 1986;147:907-9.
5. de Schipper JP, Pull ter Gunne AF, Oostvogel HJ, van Laarhoven CJ. Spontaneous rupture of the oesophagus: Boerhaave's syndrome in 2008. Literature review and treatment algorithm. *Diag Surg* 2009;26:1-6.
6. Weiss S, Mallory GK. Lesions of the cardiac orifice of the stomach produced by vomiting. *J Am Med Assoc* 1932;98:1353-5.
7. Singla R, Bhagi RP, Singh P, Goel RN, Das PK. Oesophagopleural fistula secondary to empyema thoracis. *Indian J Chest Dis Allied Sci* 1988;30:225-9.
8. Lauwers P, Van Schil P, Schroyens W, Fierens H, Vanmaele R, Eyskens E. Oesophagopleural fistula: a rare sequel of pneumonectomy. *J Thorac Cardiovasc Surg* 1996;44:266-70.