

Bilateral Pneumothoraces During Tracheostomy in a Case of Neck Injury: A Rare Case

Navneet Agarwal¹, Raghav Sharma¹ and Ritu Agarwal²

Departments of Otorhinolaryngology¹ and Anatomy², S.N. Medical College, Jodhpur (Rajasthan), India

Abstract

Tracheostomy is a life-saving procedure, performed in both emergency and elective settings. Development of bilateral pneumothoraces in adults following tracheostomy is a rare complication. We report the case of a 30-year-old male who developed bilateral pneumothoraces immediately following emergency mid-level tracheostomy. The patient was treated with bilateral intercostal tube drainage. The case is being reported to emphasise the fact that the clinician should be aware of this rare but potentially dangerous complication, so that early intervention can prevent a catastrophe. [Indian J Chest Dis Allied Sci 2018;60:253-255]

Key words: Tracheostomy, Complication, Bilateral pneumothoraces.

Introduction

Tracheostomy is a very common surgical procedure, mostly performed in an elective setting now-a-days. Occasionally, it is done as an emergency procedure for severe airway compromise. There are basically two approaches to tracheostomy: (i) open surgical tracheostomy (ST) and (ii) percutaneous dilatational tracheostomy (PDT). Pneumothorax, including bilateral pneumothoraces, is a known complication of tracheostomy and percutaneous tracheostomy.^{1,2} The risk of pneumothorax is lesser with minimal dissection. The incidence of a pneumothorax post-tracheostomy is reported to be up to 4%.³ This rate decreases to 0.8% with the technique of percutaneous tracheostomy.⁴

Pneumothorax is believed to be more common following low tracheostomy due to injury to the pleura.⁵ This complication is more common in children presumably because of severe degrees of respiratory obstruction and loose alveolar tissue in children.⁶ Others believe it to be due to high pleural dome in children. Bilateral pneumothoraces following tracheostomy in adults is rare. We report such an occurrence immediately following emergency tracheostomy.

Case Report

A 30-year-old male from Rajasthan was brought to our trauma centre with a history of road-traffic accident and head injury. Patient's attendant reported a history of loss of consciousness and vomiting. There was no history ENT bleed or convulsion. Patient's general condition was poor with a Glasgow coma

scale score of 3/15 (E1V1M1). Pupils were dilated and fixed bilaterally. There was diffuse oedema of the neck over the larynx.

The airway was secured by endotracheal intubation since no cough reflex was present on tracheal compression and the arterial oxygen saturation (SpO₂) was falling below 90%. Breathing was maintained using a Bain's circuit with oxygen flow near 6 litre/minute. After resuscitation, computed tomography of head was done which showed a left fronto-parietal-subdural haemorrhage (SDH) and left frontal contusion with significant midline shift and diffuse cerebral oedema.

Patient remained intubated for seven days in the intensive care unit under conservative treatment. Later the patient was weaned-off and extubated. After five days, the patient was discharged with a Foley's catheter and a Ryles tube *in situ*.

On the 7th week following his initial hospitalisation, the patient came to us with complaints of difficulty in breathing and huskiness of voice. On tele-endoscopy, right vocal cord movement was reduced with oedema in the glottic region. Glottic space was reduced and the patient was had minimal stridor. Contrast enhanced computed tomography of the neck (Figure 1) showed few small hyperdensities in the right true vocal cord and near the right cricoarytenoid joint (?bony fragments). Cricoid cartilage appeared discontinuous. Fullness was seen in glottis with reduced luminal size. Patient was advised to undergo an elective tracheostomy, which he declined.

[Received: September 8, 2017; acceptor after revision: March 16, 2018]

Correspondence and reprint requests: Dr Navneet Agarwal, Professor, Department of ENT, Dr S.N. Medical College, Jodhpur (Rajasthan), India; E-mail: drnavneetagarwal@gmail.com

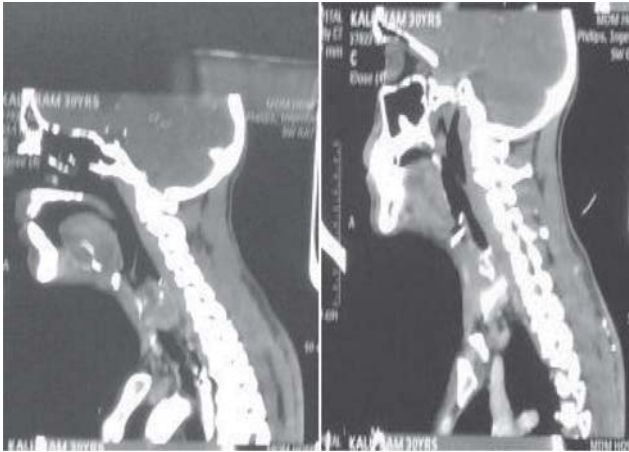


Figure 1. Contrast enhanced computed tomography of the neck showing small hyperdensities at the level of cricoid cartilage and obstruction at the level of larynx. There is no sub-glottic narrowing.

an oxygen saturation of 80% to 85%. Patient had stridor. He did not respond to medical management (inj hydrocortisone, inj theophylline and supplemental oxygen inhalation).

Emergency tracheostomy, after obtaining consent from the patient, was done with a midline vertical incision between sternal notch and cricoid cartilage under local anaesthesia infiltration. Pre-tracheal fascia was identified and separated before making incision on the trachea. At the end of the procedure, while in the recovery room, he developed cervico-facial subcutaneous emphysema. The extent and sudden appearance of swelling in periorbital region and rest of the face due to air trapping raised a suspicion of an acute pathology leading to large quantity of air leak. Even after tracheostomy, oxygen saturation did not improve. Patient's condition deteriorated as he became drowsy and was not responding to verbal commands after one hour of the tracheostomy procedure.

Radiographs of the chest and soft tissue neck showed bilateral pneumothoraces (Figure 2). High-resolution computed tomography of the thorax (Figure 3) confirmed the diagnosis of bilateral pneumothoraces with volume loss of the left lung and collapse of the left upper lobe. Sub-segmental atelectasis was also seen in dependent parts of both the lower lobes. Tracheostomy tube was *in situ* (3.5cm) from the carina.

After four days when movement in water column of under-water seal stopped, the intercostal tubes were removed. The general condition of the patient improved and he was discharged five days after intercostal drainage tubes were removed.

Discussion

Pneumothorax is classified as spontaneous and acquired. Acquired pneumothorax is sub-divided into

iatrogenic, barotraumatic, and traumatic.¹ Iatrogenic pneumothoraces may result after medical

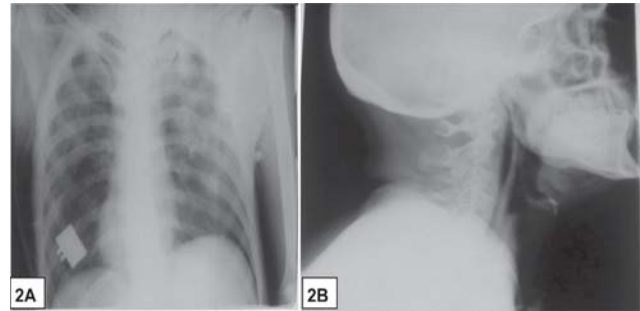


Figure 2. Chest radiograph (A) done immediately after tracheostomy showing pneumothorax; (B) radiograph of soft tissue neck (lateral view).

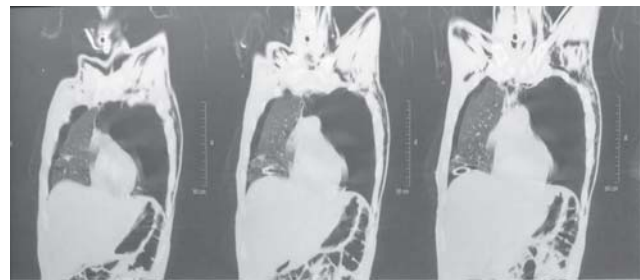


Figure 3. High-resolution computed tomography of the thorax showing bilateral pneumothoraces (almost complete collapse of lung lobes on the left side and minimal to moderate collapse on the right side).

interventions. Simultaneous bilateral pneumothoraces have been reported following trans-tracheal aspiration,⁷ surgical tracheostomy^{1,5,8-11} and percutaneous dilatational tracheostomy.¹² The incidence of iatrogenic pneumothorax and subcutaneous emphysema after percutaneous tracheostomy is 0.8% and 1.4%, respectively. Mortality after percutaneous tracheostomy is nearly 0.5%. Although pneumothorax after surgical tracheostomy has been reported in 4%¹³ to 9%¹⁴ of the patients, death associated with this procedure is extremely uncommon. Pneumothorax, regardless of its aetiology, presents with clinical symptoms depending on the amount of intra-pleural air contained. The air accumulating above a certain level may lead to life-threatening situation for the respiratory and circulatory systems. Thus, timely diagnosis and urgent intervention are crucial.

Padovan *et al*^{6,7} suggested that pneumothorax post-tracheostomy is due to the entry of air through the cervical incision and its downward passage peri-tracheally into the mediastinum during inspiration, presumably due to drop in pleural pressure which accompanies inspiration. When significant pressure exists within these mediastinal air pockets, (that may be hastened by extrinsic factors, like intermittent

positive pressure ventilation), then it may rupture into both the pleural spaces causing bilateral pneumothoraces.^{6,7} Padovan's experiments on cats suggested that hyper-extension of the neck applies mechanical tension to the mediastinal pleura and favours the bleb rupture with escape of air into the pleural space.⁶ These mechanisms are further accentuated in patients with upper airway obstruction by the powerful inspiratory efforts which generate a markedly negative intra-thoracic pressure. This negative pressure 'sucks' air rapidly from the atmosphere into the mediastinum through the edges of the tracheostomy wound, and on reaching sufficient pressure ruptures through the pleura.⁶ Hence, the resulting bilateral pneumothoraces can occur as a sudden catastrophe immediately following emergency tracheostomy or acute tracheal obstruction.^{1,9-11} Posterior tracheal wall injury in the absence of applied positive pressure is unlikely to produce pneumo-mediastinum or pneumothorax. An increased intra-thoracic negative airway pressure may facilitate the dissection of air through the tracheotomy wound into the thoracic cavity when the patient struggles to breathe against an upper respiratory tract obstruction.

In our case, we could not find the exact cause, but we believe that it could be due to laryngeal injury suffered by the patient during road-traffic accident. The injury to cricoid cartilage may have caused air leak between the tracheal and pre-tracheal fascia. This leak might have increased during the time when patient was on intermittent positive pressure respiration and later the inspiratory effort of the patient might have caused air to be sucked into the thorax. The patient refused elective tracheostomy and admission when he had minimal stridor and the intervening period of 10 days, the increased respiratory effort, increased negative intra-thoracic pressure generated during this effort and pre-existing tear in laryngeal/tracheal framework with air in the pre-tracheal space may have caused the air to dissect towards the mediastinum. The extent and sudden appearance of swelling on peri-orbital region and rest of the face due to air-trapping led to a suspicion of emergency tracheostomy leading to large quantity of air leak with pressure leading to this sequel.

In conclusion, when pneumothorax is suspected in a patient under anaesthesia or awake, the diagnosis

should be established immediately by taking the symptoms and physical examination findings into consideration. A high index of suspicion for this complication in a patient whose saturation does not improve after tracheostomy can help in early diagnosis. Early intervention can be life saving. In our case, timely intervention resulted in dramatic relief for the patient.

References

1. Tokur M, K rk o lu  C, Kurul C, Demircan S. Synchronous bilateral pneumothorax as a complication of tracheostomy. *Turk Respir J* 2006;7:84-5.
2. Li YW, Chandan GS. Bilateral tension pneumothoraces following percutaneous tracheostomy. *J Intens Care Soc* 2009;10:295-6.
3. Celik B, Sahin E, Nadir A, Kaptanoglu M. Iatrogenic pneumothorax: etiology, incidence and risk factors. *Thorac Cardiovasc Surg* 2009;57:286-90.
4. Durbin CG. Early complications of tracheostomy. *Respir Care* 2005;50:511-15.
5. Kumar KS, Nampoothiri PM, Suma R, Renu P. Pneumothorax following tracheostomy and its management. *Indian J Otolaryngol Head Neck Surg* 2002;54:236-7.
6. Padovan IF, Dawson CA, Henschel EO, Lehman RH. Pathogenesis of mediastinal emphysema and pneumothorax following tracheotomy. *Chest* 1974;66:553-6.
7. Parsons GH, Price JE, Auston PW. Bilateral pneumothorax complicating transtracheal aspiration. *West J Med* 1976;125:73-5.
8. Millard A. Double respiratory sequelae of head injury: subglottic stenosis and bilateral pneumothoraces. *Br J Anaesth* 2003;90:94-6.
9. Kumar D, O'Hare B, Timon C, Kelly D. Bilateral pneumothoraces and pulmonary oedema following tracheostomy induced by acute tracheal obstruction. *BMJ Case Rep* 2012; Aug 8; 2012. pii: bcr2012006557.
10. Whigham JR. Mediastinal emphysema and bilateral pneumothorax after tracheotomy. *Br Med J* 1945;2:47.
11. Lin YT, Zuo Z, Lo PH, Hseu SS, Chang WK, Chan KH, et al. Bilateral tension pneumothorax and tension pneumoperitoneum secondary to tracheal tear in a patient with relapsing polychondritis. *J Chin Med Assoc* 2009;72:488-91.
12. Stupnik T, Steblaj S, Sok M. Major tracheal tear and bilateral tension pneumothorax complicating percutaneous tracheostomy. *Arch Otolaryngol Head Neck Surg* 2009;135:821-3.
13. Cheng E, Fee WE Jr. Dilatational versus standard tracheostomy: a meta-analysis. *Ann Otol Rhinol Laryngol* 2000;109:803-7.
14. Stock MC, Woodward CG, Shapiro BA, Cane RD, Lewis V, Pecaro B. Perioperative complications of elective tracheostomy in critically ill patients. *Crit Care Med* 1986;14:861-3.

